



PATIENT PRESENTING CLINICAL SIGNS

Rio Blanco History: Anorexia past few days with one episode of vomiting.

SPECIES Physical Examination: N/A.

Canine Urinalysis: N/A.

CBC: N/A.

BREED Serum Biochemistry: Severely elevated liver enzyme activity and bilirubin.

Miniature Poodle Radiographic Findings: N/A.

SEX ULTRASONOGRAPHIC EXAMINATION OF THE ABDOMEN

MN *Urinary System*

Age Small urinary bladder with a normal thickness and appearance of the wall. Normal anechoic urine with no sediment or uroliths evident.

11 years Normal trigone area, proximal urethra (0.4 cm), and iliac blood vessels.

WEIGHT Normal iliac lymph nodes (0.9 cm). Ureters not visualized.

11 # Normal renal size (left 3.7 cm, right 3.8 cm), echogenic appearance, cortico-medullary differentiation, pelvis, and capsule. Bilateral pinpoint mineralization.

INTERPRETED BY *Reproductive System*

Remo Lobetti, BVSc, MMedVet (Med), PhD, Dipl. ECVIM Small hypoechogenic prostate (0.9 cm).

Adrenal Glands

Normal position, echogenic appearance, shape, and size. Left 0.53/0.49 cm, right 0.47/0.51 cm.

Spleen

Normal size (1.3 cm) and echogenic appearance. Smooth homogenous parenchyma, regular curvilinear capsule, and normal vasculature. No evidence of inflammatory, neoplastic, infarction, or infiltrative changes noted.

Liver

Enlarged with rounded edges, coarse hyperechogenic appearance, loss of portal markings, and regular curvilinear capsule. No nodules or masses evident. FNA taken with no obvious post aspirate hemorrhage.

Gall bladder

Distended containing small amount of hyperechogenic sediment. Normal thickness and echogenic appearance of the wall. Dilated cystic and proximal bile duct (0.7 cm) with normal size of the distal duct (0.2 cm). Hyperechoic appearance of mesentery surrounding bile duct. Normal appearance of the duodenal papilla.

INVOICE

304052

DATE

3/30/23

IMAGING PERFORMED BY

Sonya Myers, DVM

HOSPITAL NAME

Oviedo Veterinary Care and Emergency

REFERRING VET

Dr Lawrence


PATIENT *Gastrointestinal*

Rio Blanco Normal appearance of the stomach, duodenum, small intestine, ileo-cecal junction, and colon with no loss of layering, normal wall thickness (stomach 0.33 cm, duodenum 0.42 cm, jejunum 0.3 cm, colon 0.1 cm) and peristaltic activity, and no distension of the lumen.

SPECIES

Canine

Pancreas

Enlarged (right 1.5 cm, left 1.1 cm) with a hyperechogenic appearance and irregular capsule. Hyperechogenic appearance of the mesentery and fat surrounding the pancreas.

BREED

Miniature Poodle

Free Abdomen
SEX

Normal mesenteric lymph node (2.2 cm).
No ascites evident.

MN
Age

11 years

Primary Findings:

- Pancreatitis.
- Dilated bile duct.
- Hepatopathy.

WEIGHT

11 #

Secondary Findings:

- Renal mineralization.

INTERPRETED BY

Remo Lobetti, BVSc,
MMedVet (Med), PhD, Dipl.
ECVIM

INTERPRETATION OF THE FINDINGS & FURTHER RECOMMENDATIONS

The appearance of the pancreas is consistent with chronic-active pancreatitis with secondary obstruction of the bile duct.

Etiologies for the liver would be secondary to the pancreatitis/bile duct obstruction, reactive, vacuolar, hepatitis (acute/chronic), Leptospirosis, and infiltrate neoplasia.

Further assessment needs to be based on the pending cytology results but could include cPL/PSL assay and *Leptospira* serology/PCR.

Management of the pancreatitis would be fluid therapy as needed, anti-emetics, analgesics (opioids/NSAIDs), and low-fat intestinal diet. Monitoring of the gall bladder and bile duct would be recommended and if there is progressive distension then surgical stenting of the bile duct would be indicated.

IMAGING PERFORMED BY

Sonya Myers, DVM

HOSPITAL NAME

Oviedo Veterinary Care and
Emergency

REFERRING VET

Dr Lawrence

INVOICE

304052

DATE

3/30/23



PATIENT IMAGES

Rio Blanco **Pancreas**

SPECIES

Canine

BREED

Miniature Poodle

SEX

MN

Age

11 years

WEIGHT

11 #

INTERPRETED BY

Remo Lobetti, BVSc,
 MMedVet (Med), PhD, Dipl.
 ECVIM

IMAGING PERFORMED BY

Sonya Myers, DVM

HOSPITAL NAME

Oviedo Veterinary Care and
 Emergency

REFERRING VET

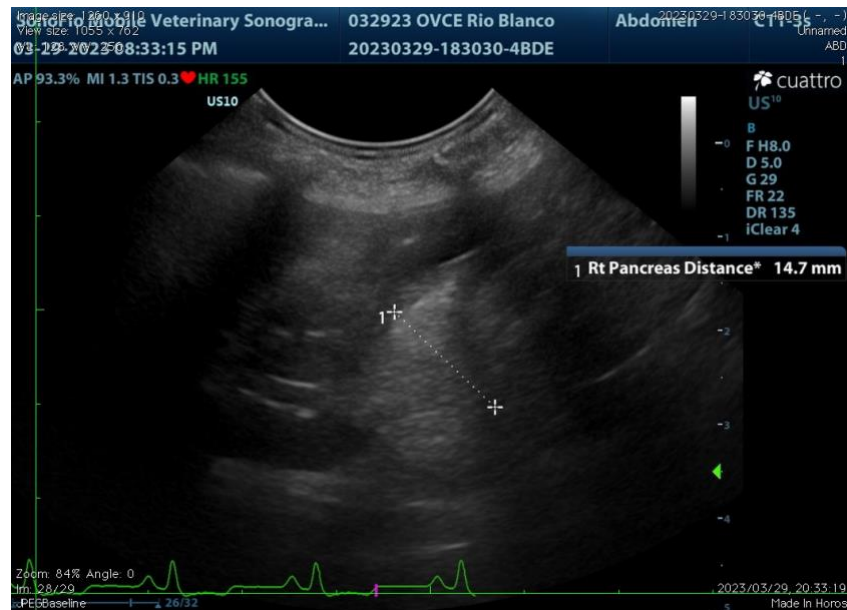
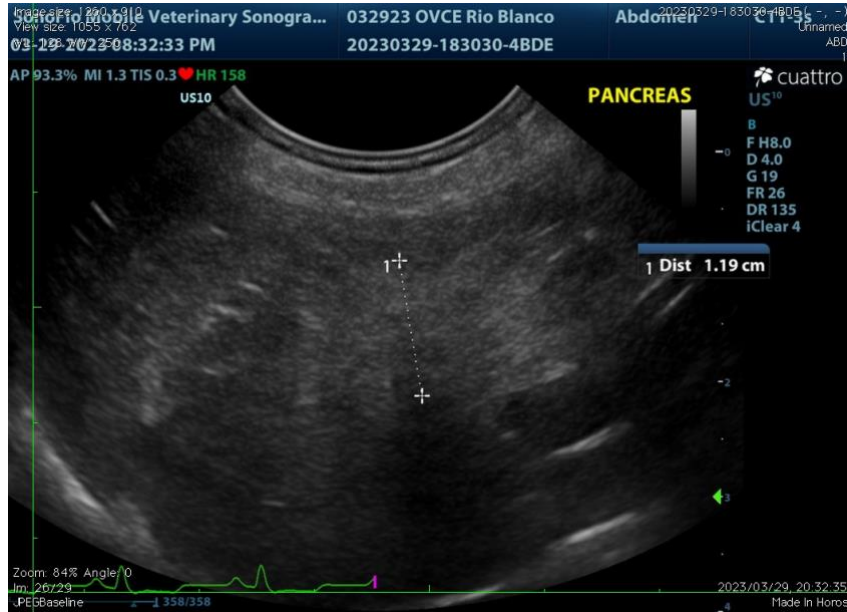
Dr Lawrence

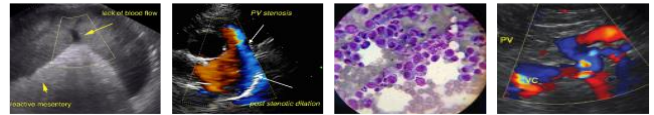
INVOICE

304052

DATE

3/30/23





PATIENT

Rio Blanco

SPECIES

Canine

BREED

Miniature Poodle

SEX

MN

Age

11 years

WEIGHT

11 #

INTERPRETED BY

Remo Lobetti, BVSc,
 MMedVet (Med), PhD, Dipl.
 ECVIM

IMAGING PERFORMED BY

Sonya Myers, DVM

HOSPITAL NAME

Oviedo Veterinary Care and
 Emergency

REFERRING VET

Dr Lawrence

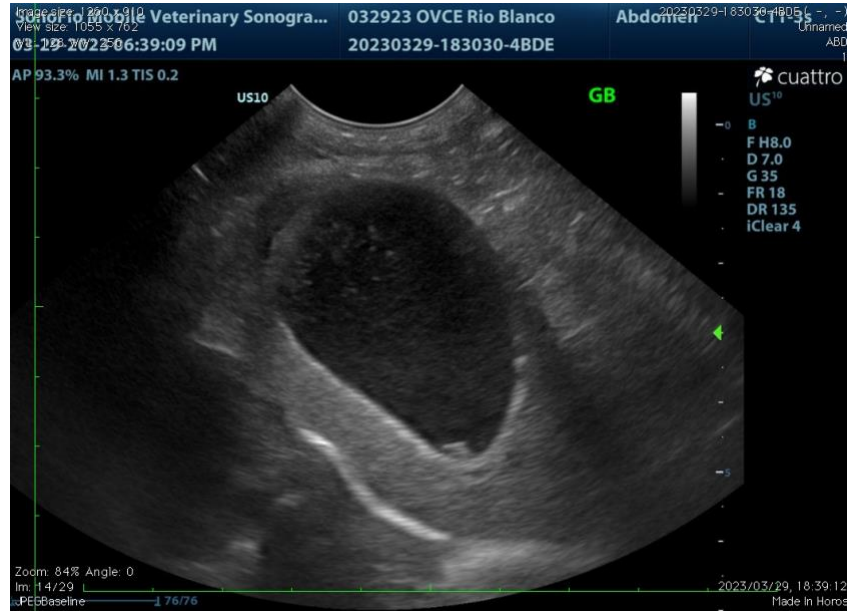
INVOICE

304052

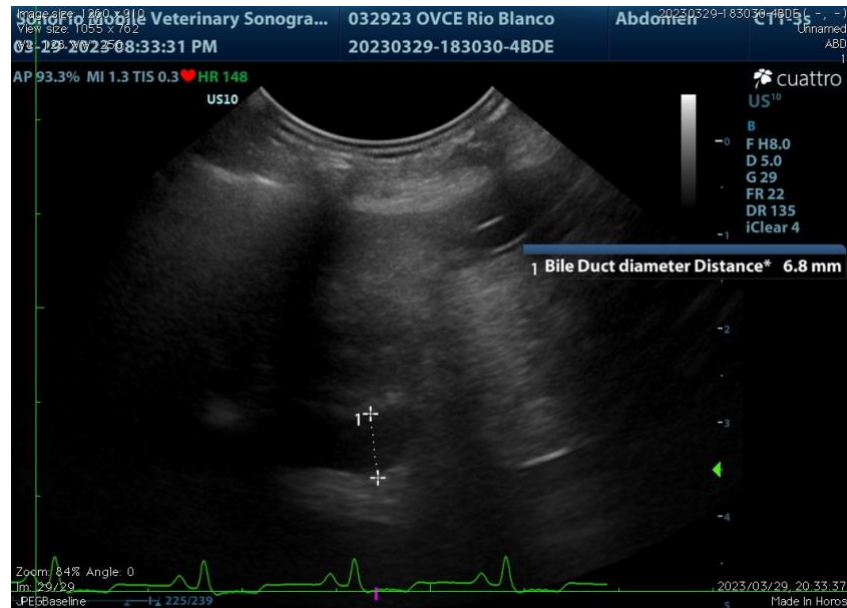
DATE

3/30/23

Gall bladder



Bile duct





PATIENT Liver

Rio Blanco

SPECIES

Canine

BREED

Miniature Poodle

SEX

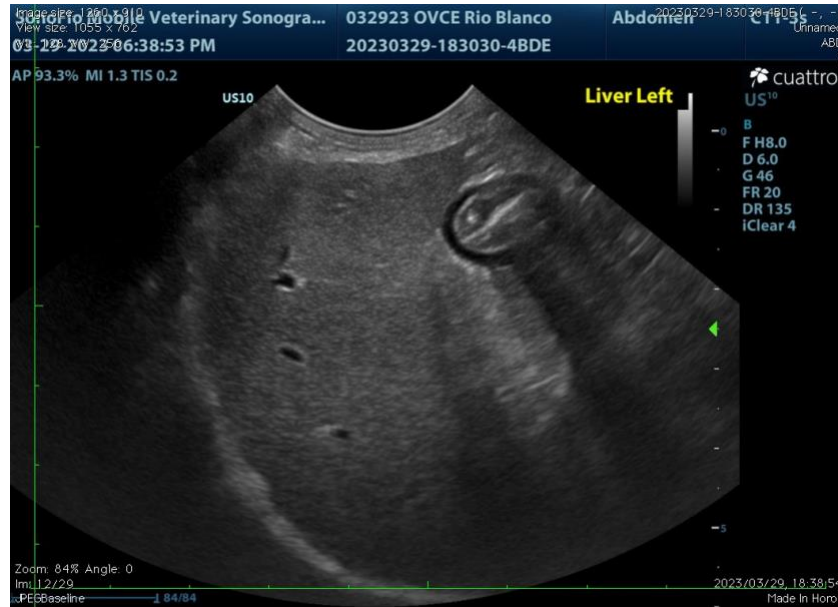MN

Age

11 years

WEIGHT

11 #



INTERPRETED BY

Remo Lobetti, BVSc,
 MMedVet (Med), PhD, Dipl.
 ECVIM

The information and recommendations provided are based on the images presented by the referring veterinarian. No evaluation can be communicated regarding pathology that was not visible in the image/video clips provided.

Thank you for this referral. If the clinical or image interpretation does not parallel your findings or if I can be of any further assistance, please contact me.

IMAGING PERFORMED BY

Sonya Myers, DVM

Remo Lobetti, BVSc, MMedVet (Med), PhD, Dipl. ECVIM (Internal Medicine)
rlobetti@mweb.co.za

HOSPITAL NAME

Oviedo Veterinary Care and
 Emergency

REFERRING VET

Dr Lawrence

INVOICE

304052

DATE

3/30/23